



## A Unique Spontaneous Subcapsular Bilioma

Ananta Shrestha,<sup>1</sup> Thupten Kelsang Lama<sup>1</sup>

<sup>1</sup>Hepatology wing, Department of Medicine, Civil Service Hospital, Kathmandu, Nepal.

### ABSTRACT

Spontaneous Subcapsular bilioma is an extrabiliary intrahepatic collection of bile in subcapsular location commonly occurring after biliary trauma or surgery. It rarely occurs in absence of any underlying biliary abnormality. We report such a case with no known underlying biliary tract abnormality except for a solitary gall stone. We bring into discussion whether this type of bilioma can be labeled as idiopathic spontaneous variety in presence of gall stone

**Keywords:** *bile; idiopathic; subcapsular bilioma.*

### INTRODUCTION

Bilioma is defined as extrabiliary collection of bile which can be intrahepatic or extrahepatic in location.<sup>1</sup> Though quite a number of case reports and series are available in literature most of them are seen in setting of iatrogenic biliary tract injury following surgery,<sup>2-4</sup> percutaneous procedures or inadvertent trauma,<sup>3</sup> to abdomen. Spontaneous biliomas are less common and invariably occur with biliary pathology mostly obstructive ones.<sup>5,6</sup> Idiopathic spontaneous subcapsular biliomas are virtually unheard of. So far only a single case report exists that discusses this entity.<sup>7</sup> We report a similar spontaneous subcapsular bilioma without an obvious biliary pathology. Further, we bring under discussion if cholelithiasis alone in absence of biliary abnormality can result in bilioma.

### CASE REPORT

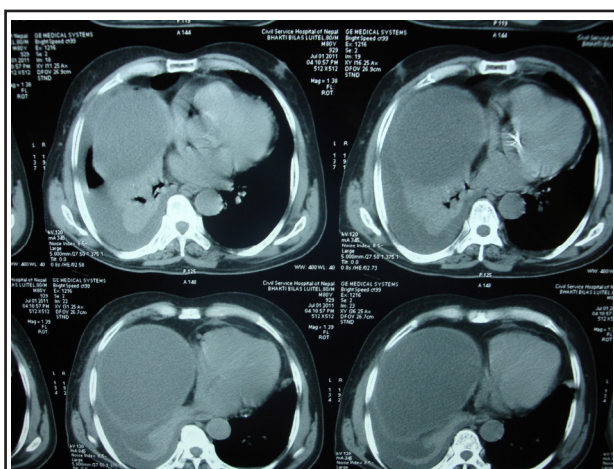
A 80 year male of chronic obstructive lung disease from eastern Nepal had right upper quadrant pain for three weeks with accompanying nausea and vomiting during first few days. It was followed by yellow discoloration

of his eyes but no fever or acholic stools. There was no history of recent surgery or trauma. He was ill looking, afebrile, and had oliguria for last one day. He was mildly icteric, anaemic had tachypnea and ankle oedema. He had tender hepatomegaly which extended 5 cm below right costal margin along with intercostal tenderness. No shifting dullness or splenomegaly was noted. He had bilateral wheezes along with decreased air entry in right lung base.

On investigation haemoglobin was 11.6 gm%, serum creatinine of 3.0 mg%. Bilirubin was 4.1 mg%, ALT 109 IU/L (2 X ULN), alkaline phosphatase level of 753 U/L (5X ULN). Noncontrast CT scan of abdomen showed a huge hypodense subcapsular cystic mass occupying most of the right lobe of liver with smooth and thin wall. There were no internal septations or any solid component. There was moderate right pleural effusion

**Correspondence:** Dr. Ananta Shrestha, Hepatology wing, Department of Medicine, Civil Service Hospital, Cha-4-415 Chhetrapati, Kathmandu Nepal. Email: anant\_02@hotmail.com, Phone: 9841152384.

and trace ascites. Gall bladder appeared hydroptic and dilated and contained a solitary calculus. No evidence of dilated intrahepatic biliary radicals or biliary tree was noted. Normal eosinophil count, negative serology for echinococcus and lack of any cystic lesion in previous scan helped to rule out the possibility of pre-existing hydatid or simple cyst of liver. ERCP was planned but due to poor general condition of the patient and lack of consent MRCP was done instead. MRCP findings corroborated with CT findings showing hyperintense subcapsular cystic lesion occupying right lobe of liver in T2 weighted images and a solitary gall bladder calculi. There were no filling defects in common bile duct, no evidence of biliary obstruction or communication of the cystic lesion with biliary channels. An upper GI endoscopy was done to visualize papilla which appeared normal with free bile flow.



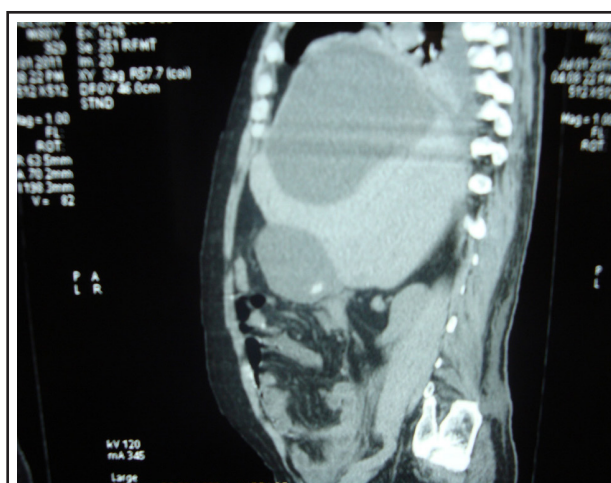**Figure 1.** Computerized tomogram of upper abdomen showing a large subcapsular collection along with mild ascites and right sided pleural effusion.

He was rehydrated, intravenous antibiotics were started. On percutaneous aspiration, the fluid was found to be bilious which was confirmed by dipstick testing. Diagnosis of spontaneous subcapsular bilioma was made. A percutaneous 8.5 fr pigtail catheter was placed in bilioma. Cytology of bile was negative for malignant cells and culture yield was sterile. Bilioma was decompressed and 2.5 litre of bile was drained. Subsequently, renal function and general condition improved during first five days. However he had tachypnea and wheezes. He later succumbed to respiratory failure owing to his background chronic obstructive lung disease.

## DISCUSSION

Our case was managed with percutaneous drainage of bilioma, following which the condition of the patient improved albeit transiently just to succumb to underlying lung disease. Several case reports have shown that percutaneous drainage can successfully treat bilioma.<sup>3</sup> In cases with underlying biliary pathology or obstruction, bile leak from the drain may fail to cease and ERCP with stenting of biliary tract in such situation solves this problem.<sup>8</sup>

Subcapsular bilioma is a rare entity. As with any other intrahepatic biliomas it occurs secondarily to surgical procedures involving biliary tract or trauma. However, there are a number of case reports on spontaneous subcapsular bilioma without antecedent history of surgery, invasive procedures in liver and biliary tract or trauma.<sup>9</sup> Spontaneous biliomas occur in setting of underlying biliary pathology, mainly biliary obstruction due to choledo-cholithiasis,<sup>5</sup> cholangiocarcinoma,<sup>3</sup> pancreatic cancer.<sup>6</sup> Spontaneous idiopathic subcapsular bilioma is an extremely uncommon condition and to our knowledge there has been only a single case report so far.<sup>7</sup> Our case is one of such spontaneous subcapsular bilioma without any identifiable biliary obstruction or calculi. Occurrence of a solitary calculus in gallbladder is an issue that created confusion. Possibility that a stone in common duct could have incited the whole event which in turn passed away spontaneously could not be ruled out. However normal biliary channels imaged in MRCP and apparently normal papilla at endoscopy underscores that gall bladder calculus could just be an incidental finding. Hence we propose it to be spontaneous idiopathic subcapsular bilioma of liver.



**Figure 2.** A sagittal image on CT scan revealing subcapsular collection along superior surface of liver (A small gall stone evident along with).

Exact mechanism and pathogenesis of spontaneous idiopathic subcapsular bilioma of liver is not understood. How such a large volume of bile (2.5 litres) accumulated within subcapsular space which appeared tense is difficult to explain as normally liver can secrete bile at pressure not more than 30 cm of H<sub>2</sub>O.<sup>3</sup> Either, pressure within the bile duct has to be high enough so that bile in the biliary tree accumulates into bilioma

through some communication. But we failed to identify any such communication between biliary tree and the bilioma cavity at MRCP. Whatever the mechanism may it be, Spontaneous idiopathic subcapsular bilioma of liver is exceedingly a rare entity. It can possibly be successfully treated with percutaneous drainage alone without ERCP and internal biliary drainage needed given that the biliary tract is normal.

## REFERENCES

1. Gould L, Patel A. Ultrasound detection of extrahepatic encapsulated bile: "biloma". *Am J Roentgenol*. 1979;139:1014-5.
2. Cervantes J, Rojas GA, Ponte R. Intrahepatic subcapsular bilioma. A rare complication of laparoscopic cholecystectomy. *Surgical endosc*. 1994;8:208-10.
3. Vazquez JL, Thorsen MK, Dodds WJ, Quiroz FA, Martinez ML, Lawson TL et al. Evaluation and Treatment of Intraabdominal Biliomas. *Am J Roentgen*. 1985;144:933-8.
4. Braithwaite BM, Cabanilla LT, Lilly M. Hepatic subcapsular biloma: a rare complication of laparoscopic cholecystectomy and common bile duct exploration. *Curr Surg*. 2003;60:196-8.
5. Ahn YH, Kim TH, Yang BJ, Oh HJ, Cho EY, Sim MR et al. A case of spontaneous biloma complicated with choledocholithiasis and chronic cholecystitis. *Korean J Gastroenterol*. 2005;46:133-6.
6. Trivedi PJ, Gupta P, Phillips-Hughes J, Ellis A. Biloma: an unusual complication in a patient with pancreatic cancer. *World J Gastroenterol*. 2009;15:5218-20.
7. Akhtar MA, Bandyopadhyay D, Montgomery HD, Mahomed A. Spontaneous idiopathic subcapsular biloma. *J Hepatobiliary Pancreat Surg*. 2007;14:579-81.
8. Bas G, Okan I, Sahin M, Eryilmaz R, Isik A. Spontaneous biloma managed with endoscopic retrograde cholangiopancreatography and percutaneous drainage: a case report. *J Med Case Reports*. 2011 Jan;6:53.
9. Gössling PAM, Alves GRT, de Silva RVA, Corrêa JRM, Marques HF, Haygert CJP. Spontaneous biloma: a case report and literature review. *Radiol Bras*. 2012;45(1):59-60.