

A SERIES OF 42 CLEFT LIP OPERATIONS IN KOSI ZONE, NEPAL

J.P. Ward M.B., F.R.C.S. (England)

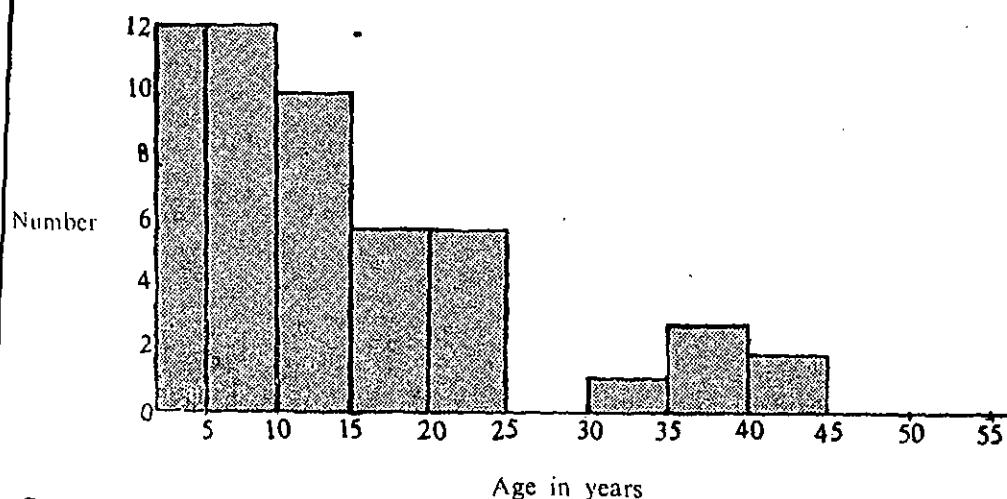
During one year of general surgery in Kosi Zone, Nepal, in Biratnagar, Dharan and mainly in the new surgical unit in Dhankuta, there has been enormous demand in the out-patient department for plastic surgery procedures, particularly that of cleft lip repair, and in Dhankuta it formed the highest incidence of attending patients in the surgical clinic.

The incidence of cleft lip is extremely high in the hill areas and thus the majority of operations were performed in Dhankuta.

Incidence

52 patients with cleft lips were seen out of 706 surgical out-patients. 42 of these were operated, and there was no selection of patients.

Age distribution



Sex

27 were male; 25 were female.

There were 23 right sided, 23 left sided and 6 bilateral.

Geographical distribution

The cleft lip patients came from Biratnagar and the surrounding Terai area, Dharan, Darjeeling, Dhankuta, Chainpur, Bhojpur, Khandbari, Terhathum, Taplejung, Ilam and many

*Surgeon, Britain-Nepal Medical Trust.

Present address: Dorset, England.

villages in between. There was a particularly high incidence from Terhathum Zilla, 20% of cases in fact.

Predisposing Factors

Cleft lip and palate is a familial disorder, and many of the operated cases were brother and sister, mother and daughter, identical twins, and patients with more distant relatives with clefts. The high incidence is due to the close relative intermarriage, which takes place, possibly due to the lesser factors of maternal viral infection in pregnancy and the increased irradiation of altitude.

Pathology of the Operated Cases

There were 27 patients with unilateral cleft lip ...

There were 5 patients with unilateral cleft lip and alveolus ...

There were 5 patients with unilateral cleft lip, alveolus and palate ...

There were 3 patients with bilateral cleft lip, alveolus and palate ...

There was 1 patient with bilateral cleft lip ...

There was 1 patient with bilateral cleft lip and unilateral cleft alveolus and palate ...

In many cases there was derotation of the ala nasi, fistula formation between nostril and the gingival sulcus, and rotation and protrusion of the premaxillary element. In three cases there was almost no premaxillary labium present, making vermilion reconstruction technically difficult.

Operation

There was no selection of cases for operation and all persons were given equal opportunity for surgical correction. Pre-operatively the patients were given a full physical examination with particular attention to pulmonary health and clinical haemoglobin level. It was not found practical to do haemoglobin investigations in the laboratory on all cases. Anaesthetic was thiopentone induction, suxamethonium bromide relaxation, endotracheal intubation and other anaesthesia with the E.M.O. portable inhaler.

The operation itself was either the Kilner, Le Mesurier, or Millard Technique, with occasional modifications to suit the case. Great care was taken in nasal reconstruction in cases with derotated ala nasi, and closure of the floor of the nose. In the repair, Lignocaine 1% with 1 in 200,000 Noradrenaline (1cc) was injected into the lips to control haemorrhage and make skin undermining simple. Mucosal suturing was with 4/0 chromic cat gut as

A Series of

the muscle layer of orbicularis oris. The skin was closed with 5/0 monofilament nylon. A Nobecutane dressing was applied. The arms were splinted for the 6 hours immediately post operation in adults and in small children (less than 6 years); the splints were left on for 7 days.

In no case was Logan's bow used. There was no routine antibiotic cover.

Results

Complete repair was managed in all 42 cases successfully.

Complications

In one case there was complete breakdown due to infection of the wound. This patient was re-operated successfully later. There was one case of partial breakdown due to trauma in the post operative period. There were 2 cases of scar retraction and a small revision operation to the lip was performed 3 months later. There was one post operative death (in a 6 week old child with bilateral cleft lip and palate) occurring 7 days post operation. The repair however was intact.

Conclusion

Cleft lip surgery can be performed in Nepal, with adequate facilities for endotracheal anaesthesia and standard operating techniques. The dangers of the immediate post operative period can only be overcome by constant nursing supervision, good suction apparatus in case of airway obstruction or vomiting, and protection of the lip.

Summary

42 patients with cleft lip successfully operated are presented and the techniques, results and complications are listed.

Give JNMA

FIRST PREFERENCE FOR

YOUR ARTICLES

Q.)

Why is the

J. N. M. A. Different

From other Advertising

MEDIA?

A.) **All its advertisements**

are Printed in

COLOUR

(Why not check and

advertise in **J.N.M.A)**