



Extensive Mucosal Erosion and Sloughing of Tongue: A Hitherto Unknown Complication of Topical Clotrimazole Preparation

Mainak Dutta,¹ Soumya Ghatak,² Gautam Biswas,³ Ramanuj Sinha²

¹Department of Otorhinolaryngology and Head-Neck Surgery, Medical College and Hospital, Kolkata, West Bengal, India,

²Department of Otorhinolaryngology and Head-Neck Surgery, R. G. Kar Medical College and Hospital, Khudiram Bose Sarani, Kolkata, West Bengal, India, ³Department of Otorhinolaryngology and Head-Neck Surgery, Murshidabad Medical College and Hospital, Berhampore, Murshidabad, West Bengal, India.

ABSTRACT

Clotrimazole, a broad-spectrum imidazole antimycotic, is a widely-used prescription as well as an over-the-counter drug for treatment of mucosal (oral, vulvovaginal) candidiasis and dermatophytes. An extremely safe and well-tolerated drug, its safety profile has been well-explored in researches and trials. The commonest complaints are almost always non-serious-pruritus, rashes, paraesthesia (stinging/burning sensation) and erythema on topical applications, and nausea, vomiting, unpleasant taste sensation and elevated liver enzymes on oral preparations (troches). However, mucosal ulceration on topical clotrimazole preparation has not been reported in literature before. We present here the first documentation of extensive bilateral erosions and necrosis of tongue involving the mucosa, submucosa and musculature on application of one percent weight/volume clotrimazole mouth paint in a 27-year-old immunocompetent woman who presented with oral candidiasis.

Keywords: *extensive bilateral ulceration and necrosis; oral candidiasis; side effect; topical clotrimazole.*

INTRODUCTION

Clotrimazole is a broad-spectrum antifungal available as an over-the-counter drug as topical preparations in the United States since 1989.¹ It enjoys an excellent safety record producing only minor adverse effects on topical application.¹ We report an unusual adverse effect of clotrimazole in the form of sloughing of tongue when applied topically for oral candidiasis.

CASE REPORT

A 27-year-old woman attended the Otorhinolaryngology clinic with complaints of white patches over the upper surface of her tongue. The patches had been developing gradually since the last 10 days and had then become confluent. It was painful and non-itching. On examination, the lesion was extensive, involving the entire dorsum of the tongue as a dirty coat without any reddish halo or surrounding oedema (Figure 1). It could be removed by a moistened tongue depressor leaving a bleeding raw surface underneath. A provisional

Correspondence: Dr. Mainak Dutta, Department of Otorhinolaryngology and Head-Neck Surgery, Medical College and Hospital, Kolkata, West Bengal, India. Email: duttamainak@yahoo.com, Phone: +91-9830737587.

diagnosis of oral candidiasis of pseudomembranous type was made. There was also evidence of angular cheilitis on the left side. It was learnt that the patient used corticosteroid inhaler for her asthma since the last seven-to-eight years. She also suffered from upper respiratory tract infection and fever about seven days back. Her general condition was otherwise within normal limits; she was afebrile, non-diabetic, had no history of significant weight loss in the last six months with no history of high-risk behaviour. Human Immunodeficiency Virus (HIV)-1 and 2 antigens were non-reactive. Commercially available topical clotrimazole preparation as oral mucosal paint in one percent weight/volume strength was advised to her, apart from multivitamin supplements and instructions to maintain proper oral hygiene.

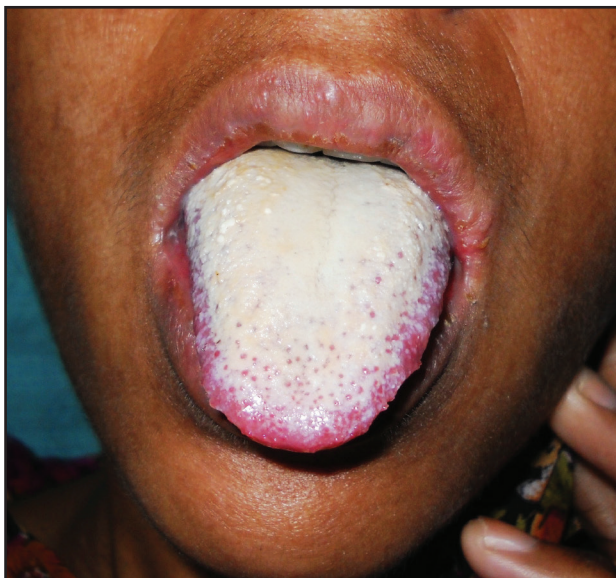

Figure 1. This 27-year-old woman presented with extensive oral candidiasis involving her tongue giving it a coated appearance. There is also angular cheilitis on the left side.

However, the patient returned three days later with painful ulcerative lesions on her tongue, especially at the lateral borders. On careful examination, the tongue was found sloughed out at the edges and had lost its normal shape and contour. The white coat had disappeared, but there was superficial erosion of the entire mucosa of the dorsum with loss of papillae, giving it a glistening smooth appearance. The erosions were deeper at the lateral borders, irregular at places, involving the sub mucosa and musculature so that the tongue resembled the head of a hammerhead shark (Figure 2a, 2b, 2c). The floor and edges of the ulcers were covered with whitish necrotic debris without any spontaneous bleeding points.

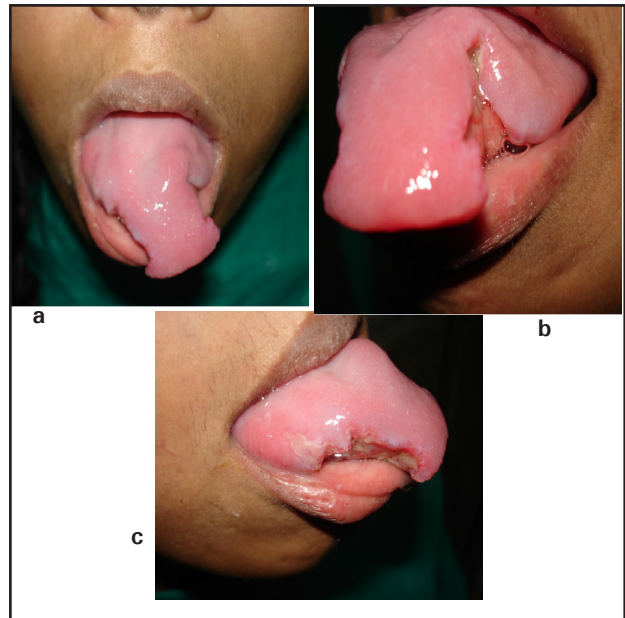


Figure 2. The tongue after application of topical clotrimazole in 1% w/v strength; it appeared deformed, smooth and glistening, without any papilla and resembled the head of a hammerhead shark. The candidial coat has disappeared [2a]. The lateral edges have undergone extensive sloughing, with erosions into the submucosa and musculature. Necrotic debris is seen on the edges and floor of the ulcers [2b, 2c].

The probable explanation was an adverse reaction to clotrimazole and it was stopped immediately. The patient did not take any other medication within this period. She was kept under close observation, and was advised oral ciprofloxacin and metronidazole with frequent mouthwash with povidone iodine and diluted hydrogen peroxide preparation. Her haematological and blood biochemistry reports including liver enzymes were unremarkable. There were signs of improvement within three days of stopping the drug. She has been followed up since then for two months with satisfactory results and has been advised to maintain a nutritious diet regime, a healthy lifestyle and to rinse her mouth thoroughly after every application of corticosteroid inhaler during or in anticipation of her asthmatic attacks.

DISCUSSION

Clotrimazole belongs to the imidazole group of antifungal agents, represented by the formula 1-(o-chloro- α , α -diphenylbenzyl) imidazole. It is a broad-spectrum synthetic antimycotic, primarily indicated for topical application in mucosal candidiasis (oropharyngeal, vulvovaginal) and dermatophytes. Its fungicidal effect is on the actively dividing fungal colony through impairment of steroidogenesis by inhibition of fungal sterol 14 α -methylase, a cytochrome P₄₅₀ (CYP51,

Erg11p)-dependent microsomal enzyme.² Apart from its antifungal effect, researches and studies in recent years on its pharmacokinetics and mechanisms of action have revealed its potential role in the therapy of sickle cell disease,³ *Plasmodium falciparum* malaria,⁴ malignancies,⁵ secretory diarrhoea,⁶ as an immunosuppressant,⁷ (in rheumatoid arthritis, inflammatory bowel disease and multiple sclerosis), and in the prevention of experimental re-stenosis post-angioplasty.⁸

With its expanding therapeutic scope, clotrimazole has been found to be extremely safe and well-tolerated, and its toxicity well-explored.¹ There has been no report of drug interactions, abuse potential or overdose potential with its topical preparation.¹ In one of the earlier studies, 15% patients were found complaining of irritation and burning sensation,⁹ more recently, out of the 555 reported adverse effects of clotrimazole from March 1975 to March 1996, 43% were regarding decrease in efficacy (therapeutic response decrease), the commonest complaints being minor ailments after topical applications like pruritus, rashes, paraesthesia (stinging/burning sensation) and erythema.¹ Both the Maximisation test and Draize Repeat Insult test performed to find out the contact sensitization of one percent clotrimazole preparation were negative. And there have been only rare instances of systemic allergic reactions to clotrimazole. With clotrimazole troches, elevation of the liver enzymes is a known complaint, along with nausea, vomiting and unpleasant taste sensation.¹⁰

Clotrimazole has been proved highly effective in chronic oral candidiasis.¹¹ Oral candidiasis is mostly caused by *Candida albicans*, a normal commensal in the oral cavity in 60% of healthy population and occurs in immunocompromised conditions like diabetes, malignancies, malnutrition and HIV/Acquired Immunodeficiency Syndrome (AIDS), or in other conditions like antibiotics, corticosteroids (including inhalers), cytotoxic drugs, pregnancy, xerostomia and prosthodontic applications.¹² The diagnosis of oral candidial infection is mostly clinical; microscopic examination of the scrapings and subsequent culture is rarely needed.¹⁰ It is clinically differentiated from leukoplakia by the property of being scraped off by a tongue depressor. It presents as one or more of the three gross clinical types, i.e. pseudomembranous, atrophic ('burning mouth syndrome') and perioral angular cheilitis.^{13,14} Angular cheilitis often harbours

mixed flora of bacteria and fungi, with *Candida* sp. present in ~80% cases.¹⁵

Our patient presented with extensive oral lesions over the dorsum of her tongue which peeled off on gentle scraping leaving a raw surface underneath. The diagnosis of pseudomembranous candidiasis was clinical, that was however indirectly confirmed when the lesion responded to topical clotrimazole advised as an empirical treatment judged on the lesion's clinical appearance. She also had coexistent angular cheilitis on her left side which also responded to the treatment. What was unexpected was the sloughing out of the tongue on application of topical clotrimazole. Differential diagnoses could have been an allergic reaction to clotrimazole, an erythema multiforme-like response, or Steven-Johnson-like reaction. However, such extensive sloughing is truly unprecedented. The slough appeared bilaterally, had extensive necrotic base and edges that eroded through the submucosa and the musculature of tongue. The patient took corticosteroid inhaler since seven-to-eight years, but had poor knowledge regarding its side effects as she did not have the habit of regular and proper oral rinse that is generally recommended after every use of the inhaler. The recent episode of infection and fever acted as a precipitating factor and these could explain the occurrence of oral candidiasis in this otherwise healthy woman.

Adverse effect of clotrimazole of this nature has never been mentioned in the published literature before. An extensive search through the PubMed/MEDLINE databases with keywords 'clotrimazole', 'candidiasis' and 'side effects' revealed no documentation of mucosal sloughing. Thus, our case represents the first report of mucosal sloughing secondary to topical clotrimazole. And the extent of erosion and underlying soft tissue involvement has made it more interesting and worth presenting.

Clotrimazole is a safe, well-tolerated drug. Its safety profile has been well-studied and majority of its adverse effects on topical application are limited to non-serious complaints like pruritus, paraesthesia, rashes and erythema. However, mucosal sloughing in the form of tongue necrosis with topical application of clotrimazole for oral candidiasis has never been reported before. Thus it becomes evident that the use of even the most well-studied, safe and well-tolerated drug should be followed by proper vigilance and careful observation for any side effects, which may be either exceptional or unexpected or both.

REFERENCES

1. Topical antifungal drug products for over-the-counter human use; proposed amendment of final monograph. Department of Health and Human Services, Food and Drug Administration. Federal Register /Vol. 66, No. 103 / Tuesday, May 29, 2001 /Proposed Rules. p29059-63.
2. Parker JE, Merkamm M, Manning NJ, Pompon D, Kelly SL, Kelly DE. Differential azole antifungal efficacies contrasted using a *Saccharomyces cerevisiae* strain humanized for sterol 14 α -demethylase at the homologous locus. *Antimicrob Agents Chemother*. 2008 Oct;52(10):3597-603.
3. Brugnara C, Gee B, Armsby CC, Kurth S, Sakamoto M, Rifai N, et al. Therapy with oral clotrimazole induces inhibition of the Gardos channel and reduction of erythrocyte dehydration in patients with sickle cell disease. *J Clin Invest*. 1996 Mar 1;97(5):1227-34.
4. Trivedi V, Chand P, Srivastava K, Puri SK, Maulik PR, Bandyopadhyay U. Clotrimazole inhibits hemoperoxidase of *Plasmodium falciparum* and induces oxidative stress—proposed antimalarial mechanism of clotrimazole. *J Biol Chem*. 2005 Dec;280(50):41129-36.
5. Aktas H, Fluckiger R, Acosta JA, Savage JM, Palakurthi SS, Halperin JA. Depletion of intracellular Ca²⁺ stores, phosphorylation of eIF2 α , and sustained inhibition of translation initiation mediate the anticancer effects of clotrimazole. *Proc Natl Acad Sci USA*. 1998;95:8280-5.
6. Tian M, Dong MQ, Chiu SW, Lau CP, Li GR. Effects of the antifungal antibiotic clotrimazole on human cardiac repolarization potassium currents. *Br J Pharmacol*. 2006 Feb;147(3):289-97.
7. Jensen BS, Hertz M, Christophersen P, Madsen LS. The Ca²⁺-activated K⁺ channel of intermediate conductance: a possible target for immune suppression. *Expert Opin Ther Targets*. 2002 Dec;6(6):623-36.
8. Kohler R, Wulff H, Eichler I, Kneifel M, Neumann D, Knorr A et al. Blockade of the intermediate-conductance calcium-activated potassium channel as a new therapeutic strategy for restenosis. *Circulation*. 2003;108:1119-25.
9. Clayton YM, Connor BL. Comparison of clotrimazole cream, Whitfield's ointment and Nystatin ointment for the topical treatment of ringworm infections, pityriasis versicolor, erythrasma and candidiasis. *Br J Dermatol*. 1973 Sep;89(3):297-303.
10. Guidelines for the Prevention and Treatment of Opportunistic Infections Among HIV-Exposed and HIV-Infected Children. USA: Centers for Disease Control and Prevention; 2009 Sep. 166 p. Report No.: RR-11.
11. Kirkpatrick CH, Alling DW. Treatment of chronic oral candidiasis with clotrimazole troches: a controlled clinical trial. *N Engl J Med*. 1978 Nov 30;299(22):1201-3.
12. Greenspan D. Treatment of oral candidiasis in HIV infection. *Oral Surg Oral Med Oral Pathol*. 1994;78(2):202-10.
13. Lynch DP. Oral candidiasis: history, classification, and clinical presentation. *Oral Surg Oral Med Oral Pathol*. 1994 Aug;78(2):189-93.
14. Lewis MA, Samaranyake LP, Lamey PJ. Diagnosis and treatment of oral candidosis. *J Oral Maxillofac Surg*. 1991;41(9):996-1002.
15. Ohman SC, Dahlén G, Möller A, Ohman A. Angular cheilitis: a clinical microbial study. *J Oral Pathol*. 1986;15(4):213-7.