



Fetal Craniotomy

Bikash Shrestha,¹ Sandip Gupta,² Lomi Chawnglut,² Bipindra Khaniya²

¹National Academy of Medical Sciences, Bir Hospital, Kathmandu, ²Lamjung District Community Hospital, Lamjung, Nepal.

ABSTRACT

Nowadays, even in developing countries Cesarean section is the most common method of delivery for the breech presentation. However, in rural parts of the countries still vaginal route is the only option. Trauma to the after coming head is the common issue among the contributors of birth trauma during breech delivery. Entrapment of after coming head is an unpredictable obstetrical emergency. If the fetus is alive, options from application of obstetric forceps to giving Dührssen incisions can be kept in choice. Cesarean section is done when all the methods fail to deliver the head. But, when the fetus is not salvageable, delivery of after coming head by craniotomy can reduce unnecessary morbidity of Cesarean section. In the present report, a case with entrapment of after coming head of dead preterm fetus for 6 hrs of home delivery was described and the management of this condition was reviewed.

Keywords: *after coming head; breech; craniotomy; obstetrical emergency.*

INTRODUCTION

It is well accepted that Breech presentation increases the risks of morbidity and mortality to both fetus and mother.¹ The major contributor to the perinatal loss during breech delivery is birth trauma, especially trauma to after coming head.² There have been cases of successful outcomes after severe head entrapment of term infants using different techniques like application of obstetric forceps, administration of halothane, an intravenous dose of nitroglycerine to mother or extension of cervical incision.³ But when the baby is dead in utero, the useful technique can also be craniotomy to reduce the unnecessary morbidity of Cesarean section to deliver the dead fetus.⁴ Recently we encountered a case of breech presentation with intrauterine fetal death due to prolonged labour with entrapped after coming head due to suspected hydrocephalus. As other techniques which we had available failed, the entrapped head was delivered by craniotomy.

CASE REPORT

A 24 years woman Mrs SMT G₃P₂L₁ at 34 weeks period of gestation with no antenatal check-up was brought in ambulance with the history of unable to deliver the breech for 6 hrs. On general examination the woman was in agony. However her vital parameters were stable with pulse of 100/min, regular, afebrile, BP of 120/90 mm Hg, RR of 20/min and SpO₂ of 100% in room air. Female baby was delivered up to the abdomen and her lower limbs and abdomen was bluish black. Heart sounds were not audible and baby was not alive. Immediately, the woman was taken to the labour room. Bilateral Upper limbs were delivered and delivery of after-coming head was tried with Mauriceau–Smellie–Veit manoeuvre (MSV). As the after-coming head could not be delivered with MSV technique, low lying forceps

Correspondence: Dr. Bikash Shrestha, Nepal Academy of Medical Sciences, Bir Hospital, Kathmandu, Nepal. Email: shrestha811@gmail.com, Phone: +977-9841486393.

was applied (as Piper's forceps was not available) and delivery attempted, but failed. As we didn't have nitroglycerine and halothane, craniotomy was done from the left aspect of the nuchal prominence at the occipital bone behind the mastoid with the help of Simpson's perforator. After suctioning of 2000 ml of cerebrospinal fluid along with pieces of brain matters, the head was delivered spontaneously. Placenta was delivered by controlled cord traction. Vaginal wall and cervix were checked for signs of trauma. Bleeding from the uterus was controlled with uterine massage, Inj. Oxytocin 10 units IM and Inj. Methergin 0.2 mg IM. Foleys catheterization was done. Placenta was checked for its completeness. Baby was examined which revealed female baby with no obvious congenital anomalies except for the oedematous face and head.

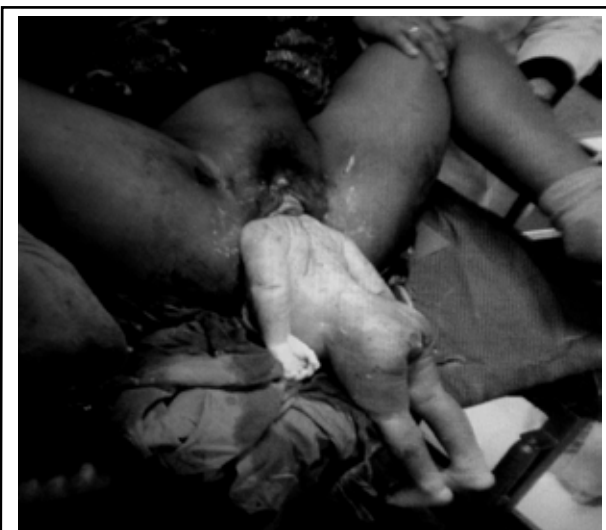

Figure 1. Entrapped after coming head.

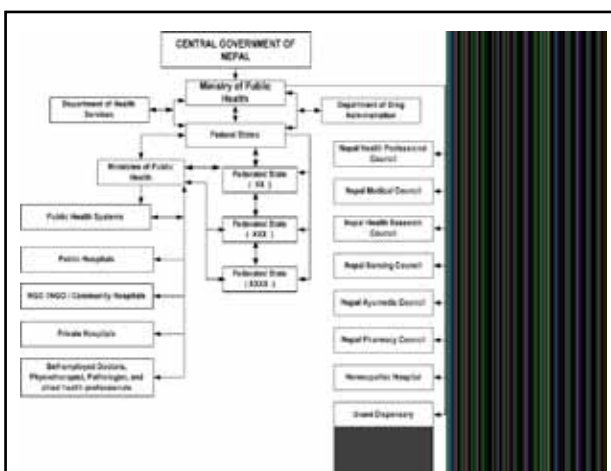


Figure 2. Site of Craniotomy.

Patient was admitted with IV antibiotics for 3 days. After 3 days, the patient was discharged on request along with catheter for 1 week and was advised to

come on follow up after 1 week. On follow up foley's catheter was removed and she was advised to follow up in future as needed.

DISCUSSION

Entrapment of after coming head during the vaginal delivery of breech is the most serious complication.¹ For preterm vaginal breech deliveries the incidence is 7.7 % and for Cesarean section is 5.2%.³ It is an unpredictable obstetrical emergency and despite proper and adequate management it may occur in about 1 in 12 vaginal breech deliveries without any warning.⁵ Unlike in the delivery of baby with vertex presentation where molding occurs, the head of fetus in breech presentation must come through the birth canal without having any molding.² So, in this emergency situation choices among optimal options available needs to be made very quickly.⁶ To release the entrapment, one of the following measures may be tried: (i) attempt the Dührssen incisions by cutting the cervix at 2, 6, and 10 o'clock to increase the size of the cervical aperture, (ii) use of agents like betamimetics, nitroglycerine or inhalational anaesthesia for uterine relaxation, or (iii) perform an emergency Cesarean section (abdominal rescue).¹ If the fetus is already dead or unsalvageable because of hydrocephalus as in our case, decision and attention can be given ensuring a safety of mother and for good maternal outcome. At this moment destructive procedure like fetal craniotomy can be carried out to deliver the after coming head.³ In many developed countries it is of historical interest only⁷ but in developing countries where the reach of even basic obstetrical care is way below satisfactory for the majority of the population, this technique can save the patient and also can be applied in place of unnecessary Cesarean section.⁸ In a study done in Jinnah Postgraduate Medical Centre Karachi over a period of 6 years, craniotomy was performed in 32 fetuses with a maternal morbidity of 12.5% with no maternal death. Maternal morbidity included, cervical tears (2 patients), vaginal tear (1 patient), and total abdominal hysterectomy (1 patient) due to primary postpartum haemorrhage. The conclusion of the study was that craniotomy done in selected cases was safe and quicker than doing Cesarean section. Though unpleasant to perform, it is a great relief to the patient and her family.⁴ So it will be not wrong to say that, craniotomy is of value in places which deal with a large number of cases of obstructed labours and intrauterine deaths due to lack of adequate antenatal care, and should not be abandoned totally.

Even if Craniotomy has no place in modern obstetrics, it remains an important weapon in the armoury of the

third world obstetrician. It is hence necessary for all doctors practicing in developing countries to be aware that craniotomy can be a very useful procedure.⁹

ACKNOWLEDGEMENTS

We would like to thank Human Development and Community Service (HDCS), Lamjung Community District Hospital (LDCH), Staffs from Maternity Ward, Mr. Yubraj Acharya, Hospital Administration Officer, LDCH, Mr. Laxman Adhikari, Police personnel, LDCH

REFERENCES

1. Wongwananuruk T, Rattanachaiyanont M. Entrapment of After-coming Head in Cesarean Breech Delivery of Term Pregnancy: A Case Report. *Siriraj Med J.* 2008;60(6):356-9.
2. Shushan A, Younis JS. McRobertsmaneuver for the management of the aftercoming head in breech delivery. *GynecolObstet Invest.* 1992;34(3):188-9.
3. Robertson PA, Foran CM, Croughan-Minihare MS, Kilpatrick SJ. Head entrapment and neonatal outcome by mode of delivery in breech deliveries from 28-36 weeks gestation. *Am J ObstetGynaecol.* 1996;17(6):1742-9.
4. Tariq TA, Korejo R. Evaluation of the role of craniotomy in developing countries. *J Pak Med Assoc.* 1993 Feb;43(2):30-2.
5. Myers SA, Gleicher N. Breech delivery: why the dilemma? *Am J Obstet Gynecol.* 1987 Jan;156(1):6-10.
6. Menticoglou SM. Symphysiotomy for the Trapped Aftercoming Parts of the Breech: A Review of the Literature and a Plea for Its Use. *Aust N Z J Obs& Gynae.* 1990;30:1-9.
7. Myerscough P, R. Munro Kerr's Operative Obstetrics. 9th ed. London: BailliereTindall; 1977;572.
8. Philpott RH. Obstructed labour. *Clin. ObstetGynaecol.* 1980;7:601-19.
9. Lawson, J.B. Obstructive labour, in obstetrics and gynaecology in the tropics and developing countries. London:Arnold;1967;193.